

Esthetic Restorations Fractured Anterior Tooth Using Direct Composite Restoration: A Case Report

Hanali Abu Shilbayih*

Department of Orthodontics and Pediatric Dentistry, Al-Quds University, Jerusalem, Palestine.

ABSTRACT

Introduction: Traumatic dental injuries are a common occurrence. Numerous treatment options are available for restoring such a tooth. Careful examination of tooth, tooth fragments and fracture line are important aspects before finalising treatment plan. Injuries such as these can cause pulpal as well as esthetic concerns and should be carefully evaluated by clinical and radiographic means. Clinical findings may range from minimal thermal and pressure sensitivity to the acute distress of a pulp exposure. Direct resin composite restorations should wherever possible be preferred due to the speed and possibility of obtaining good results.

Objective: The objective of this case report is to describe the clinical sequence for restoration of a maxillary central incisor that presented a crown fracture using an immediate insert technique for resin composite with a modification to obtain dentin layer.

Case Report: A 13years girl patient sought treatment after she fractured tooth #21. The restoration was performed with resin composite using the immediate technique.

Conclusion: The restoration of fractured anterior teeth can be performed quickly with the use of resin composites of different opacities and the use of the technique of immediate insertion proposed in this case report.

Keywords

Direct restoration, Permanent anterior teeth, Trauma, Uncomplicated crown fracture.

Corresponding Author Information

Hanali Abu Shilbayih

Department of Orthodontics and Pediatric Dentistry, Al-Quds University, Jerusalem, Palestine, Tel: +972 52-505-2060

Received: April 19, 2023; **Accepted:** May 11, 2023; **Published:** May 15, 2023

Copyright: © 2023 ASRJS. This is an openaccess article distributed under the terms of the Creative Commons Attribution 4.0 International license.

Citation: Shilbayih HA. Esthetic Restorations Fractured Anterior Tooth Using Direct Composite Restoration: A Case Report . J Oral Dental Care. 2023;1(1):1-5.

Introduction

Coronal fracture by trauma is the most frequent type of dental injury in the permanent dentition [1]. Two generic groups of predisposing factors exist which lead to trauma. Group 1: fracture of previously sound teeth of children and teenagers resulting from trauma during sports activities; from falls and bicycle, skate and ski accidents; or during other leisure activities. Group 2: fracture of the teeth of adult patients, which have been rendered fragile by large restorations, caries lesion, and/or endodontic treatment.

Fracture may result from trauma in automobile accidents, sports activities, fights, and even from occlusal function or parafunctional stresses [1-4].

The worldwide prevalence of traumatic dental injuries ranges between 6%-37% [2-4]. Seasonal variations in the prevalence of trauma have also been reported [5-7]. Dental trauma (DT) of the incisors and their supporting tissues, which is one of the most challenging dental emergency situations, requires immediate

assessment and management due to psychological and physical reasons [4]. This is especially important for young permanent teeth because of continuing development in order to minimize undesired complications [4].

Dental trauma often has a severe impact on the social and psychological well-being of a patient.[2] Coronal fractures of permanent incisors represent 18-22% of all trauma to dental hard tissues, 28-44% being simple (enamel and dentin) and 11-15% complex (enamel, dentin and pulp). Of these 96% involve maxillary central incisors [5].

Intensity of trauma, direction of the trauma, elasticity of the substance, and tolerance of the soft tissue are the major factors that determine the extent of the fracture [5]. Various injuries may occur on dentition and cause fractures of different classifications [6]. The most frequent type is enamel-dentin fracture with or without pulp exposure [3], the predictable esthetic restoration of broken incisal edge of maxillary central incisors is a demanding and technique sensitive procedure. Its success is dependent on operator's skills and knowledge and on adhering to a systematic and problem solving approach [4]. A logical method is used to build up morphologically correct composite restorations by careful selection of composite shades, tints and opaques. In accurate combinations, an illusion of varying translucencies and opacities become visible over natural tooth structure [1-4].

The dental composite has emerged as a top ranked material over other direct restorative counterparts [8]. Their evolution since their introduction in dentistry has resulted in better bonding, optical and handling properties. Their performance has also been supported by many longevity studies [9].

In the present article, an esthetic rehabilitation of fractured anterior teeth restored with direct composite resin is presented.

Case Report

A 13-year-old girl was reported to the my Paediatric Dental Clinic,Jerusalem,Palestine for the treatment of fractured upper front teeth with esthetic concern. Patient gave history of trauma 2months back due to fall from a bicycle. Clinical examination revealed Ellis class II (uncomplicated) fracture in relation to 21. (Figure 1). The tooth was asymptomatic without any associated soft or hard tissue injuries to the supporting tissues. Intraoral periapical radiograph confirms the absence of pulpal or periapical pathosis.

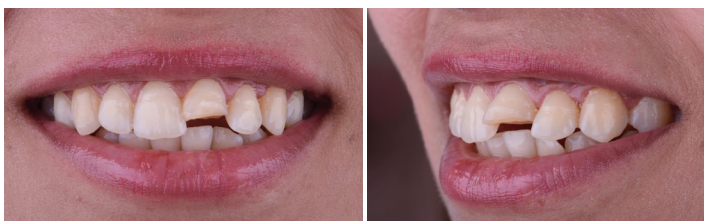

Figure 1: Pre-operative view.

The clinical and radiographic examinations showed the fracture did not involve the pulp. Because the fragment was missing, the decision was to restore the fracture immediately by direct composite resin using a freehand technique as a simple approach (Figure 2).

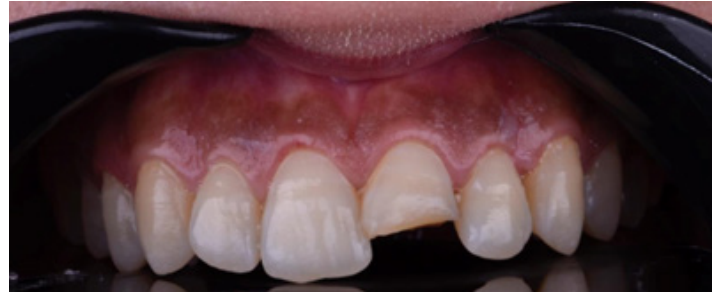

Figure 2: Intraoral photograph. Close view of the coronal fracture of tooth #21 involving enamel and dentin without pulp exposure.

The operative field was isolated and the gingiva displaced with ligated rubber dam (Figure 3). The adjacent teeth were protected with polyester tape. The enamel surface was conditioned with 37% phosphoric acid, and the adhesive was then applied on the facial and lingual surfaces (Figure 4) and polymerized according to the manufacturer's instructions.

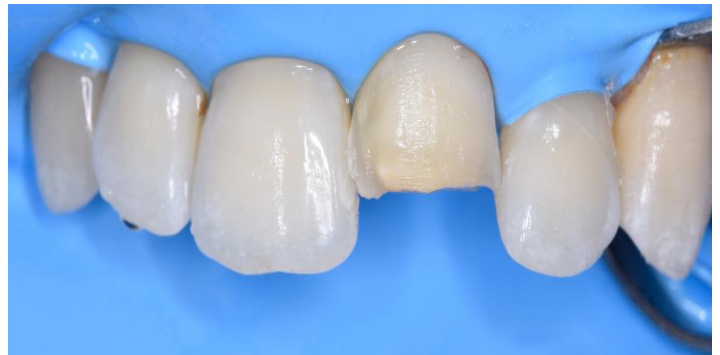

Figure 3: Rubber dam isolation of the operative field.

The silicone matrix was positioned lingually to provide a well-contoured restoration (Figure 5). Resin matching the lingual enamel was applied with the matrix in position .After polymerization of this increment with the matrix in position, the lingual and incisal contour was established. Dentin resin was then applied to the middle third, leaving room for the creation of a dentinal lobe in the incisal region. The incisal halo was made by using the opalescent translucent resin of the OM system followed by a layer of white stain on that halo to simulate the opacity of this region. (Figure 6) The dentin mamelons were made with clear resin, and opalescent resin was applied between the mamelons the enamel layer was applied to the facial surface and spread with the aid of a polyester strip and brush (Figure 7).

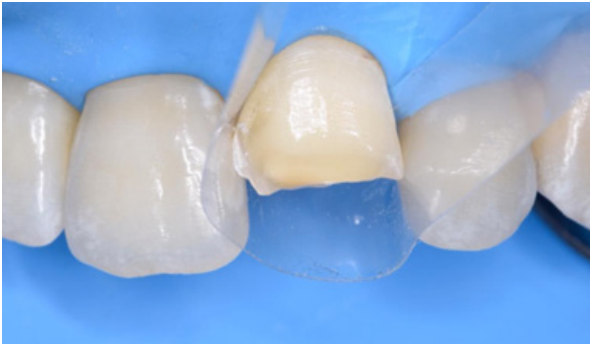


Figure 4: Application of the adhesive system and polymerization according to the manufacturer’s instructions.

Before finishing and polishing, the last layer of composite was photopolymerized for 1 additional minute under glycerine air-block; this additional step is important to increase the hardness of the superficial layer as it increases the degree of conversion of composite that prevents the deterioration of the restoration and the interface with the tooth (Figure 8).

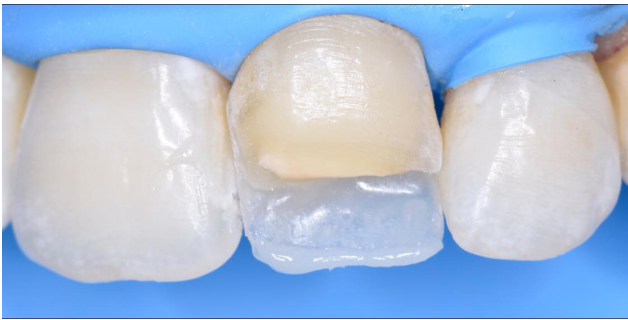

Figure 5: Facial, lateral, and incisal views immediately after application and polymerization of the resin to form the lingual “shell” with enamel resin.

The micro texture was obtained with the aid of an extra fine Diamond bur. The final polishing was performed with thin grit abrasive sandpapers and felt discs with diamond past. The final restoration is seen in figures 8, 9.

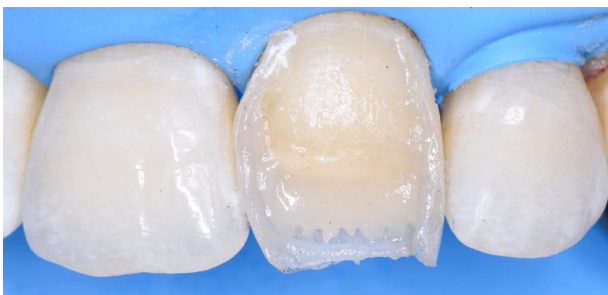

Figure 6: Application of LD dentin resin up to approximately half the width of the bevel. Observe the spaces between the developmental lobes, left when applying the opaque resin, in which the translucent incisal resin (OM) will be placed.

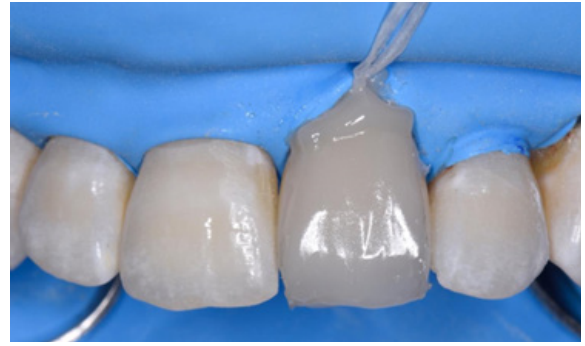

Figure 7: Insertion of translucent incisal resin (OM) between dentin mamelons. Then, the resin was applied in the LE color over the entire facial surface of the restoration to simulate the enamel.

Discussion

Dental traumas are estimated an increasing public health problem that affects permanent dentition among children and teenagers. The majority of dental injuries happen in the anterior region, affecting mainly the maxillary central incisors that can have a significantly negative functional, esthetic and psychological influence. Several techniques can be used for restoring fractured teeth, either by indirect or direct restorations, or in some situations by reattachment of the fragment. Direct composite restorations for non-complex crown fractures with missing fragment represents the most minimally invasive method [10,11].

Composite restorations offer a cost effective treatment alternative where esthetics is a major concern [2,3,12]. The survival rates of these anterior composites were reported to be extremely satisfactory even in patients with worn dentition. With improvements in the bonding chemistry and introduction of nano-composites, it is speculated that the success rate of composites will improve even further [3,13,14].

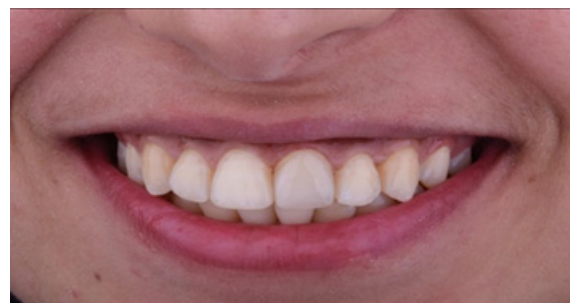

Figure 8: Finishing and polishing of the restoration with abrasive disks, fine diamond rotary instruments, rubberpoints, and a felt disk with polishing paste.

The composite resins provide satisfactory treatments results for even young and adult patients, but it is indicated to adults when the volume, length or number of composite restorations is limited [2-5,8]. This study presented a young patient with good results using only composite resins [3,4,13,14]. Initial planning is essential for the best esthetic and functional results from restorative

procedures. The use of some planning strategies enables greater dental structure preservation and result predictability [11,15,16]. The choice of resin composite should be focused on aspects related to the strength and aesthetics. Within this context, the composite layering is the key to obtaining esthetically successful restorations [14,16].

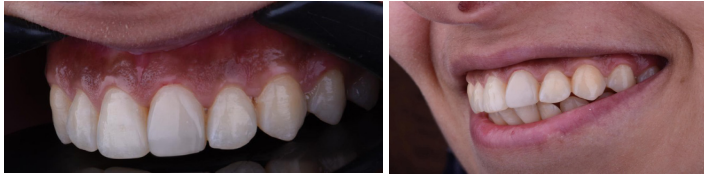

Figure 9: Smile view, harmony of shape, color, and function of the tooth have been restored.

According Nahsan et al., young teeth show a naturally high value and thus require resins with such characteristics; in consequence, the reproduction of enamel should be done with composite resins that presents transparent characteristics [17].

Some authors reported that 35% of all children and adults suffer dental accidents to their permanent teeth [2,3,5,18-21].

Microhybrid composite was utilized for the restoration of outer surfaces. Thus, more polished and smoother surfaces are obtained. A second visit is recommended 1 week after the restorative procedure because of the water sorption of composite resins. As most of the water sorption can be observed during the first week, the polishing procedures can be performed in the second visit in order to get a more esthetic view [12,13,22,23] (Figure 8).

In our case (Figure 1), an economical and time-saving novel technique has been described for direct composite restoration in a young patient with uncomplicated fractured maxillary anterior tooth. As restoring a fractured tooth is a complex procedure, this technique can prove as a simple, effective and appropriate technique that will fulfill all the requirements of dental personnel. This technique can also prove to be easy for inexperienced beginner clinicians without requiring special skills in providing the patients with direct composite restorations. The first construct the palatal layer with enamel resin, we started by making the dentin layer. The rationale behind the use of this technique was that large Class IV cavities and large fractures, the immediate technique with digital support results in a palatal enamel layer usually very labially tipped, making difficult to obtain restorations with opacity compatible to that of the surrounding teeth (Figure 9).

The dentist must be prepared to solve the problem from both the therapeutic and emotional standpoint. Consequently, the dentist must have control of the situation, showing knowledge, serenity and security to both the patient and parents. The professional should establish an adequate treatment planning, minimizing further sequelae and providing a higher probability of the traumatized tooth maintenance until the patient reaches the adult age [23-25].

Conclusions

Direct composite restorations represent the best immediate solution for the patient with fractured teeth in the aesthetic area, especially when the fractured fragment is missing. Restoration of anterior teeth is regarded as a challenge to most dentists, but following the natural layering concept using one shade of enamel and one shade of dentin with the opalescent composite can be considered the simple approach to obtain lifelike mimicking restorations.

References

1. Andreasen JO, Andreasen F, Andersson L. Textbook and Color Atlas of Traumatic Injuries to the Teeth. 3rd ed. St. Louis, MO: Mosby; 1994.
2. Abu-Hussein Muhamad. Restoring Fractured Anterior Tooth Using Direct Composite Restoration: A Case Report. Global Journal of Dental Sciences. 2019; 1:1.
3. Abdulgani Azz, Abdulgani M, Abu-Hussein M. Fractured Anterior Tooth Using Direct Composite Restoration: A Case Report. IOSR Journal of Dental and Medical. 2017; 16: 61-65
4. Abu-Hussein M, Abdulgani Az, Ziyad M, et al. Autogenous Tooth Fragment Reattachment; A 12 -Years Follow-Up. Journal of Dental and Medical Sciences. 2016; 15: 85-90.
5. Abu-Hussein Muhamad, Nezar Watted, Azzaldeen Abdulgani, et al. Prevalence of Traumatic Dental Injury in Arab Israeli Community. IOSR Journal of Dental and Medical Sciences. 2016; 15: 91-98.
6. Abu-Hussein Muhamad, Abdulgani Azzaldeen, Abdulgani Mai. Esthetics of Class IV Restorations with Composite Resins. Journal of Dental and Medical Sciences. 2016; 15: 61-66.
7. Abu-Hussein M, Watted N, Abdulgani A, et al. Anterior Dental Esthetics in Primary Teeth. International Journal of Public Health Research. 2015; 3: 25-36.
8. Mehta SB, Banerji S, Millar BJ, et al. Current Concepts On The Management Of Tooth Wear: Part 4. An Overview Of The Restorative Techniques And Dental Materials Commonly Applied For The Management Of Tooth Wear. British Dental Journal. 2012; 212: 169-177.
9. Roberson, Heymann, Swift. Additional conservative esthetic procedures. 4th ed. Missouri: Mosby; 2002. Sturdevant's Art and Science of Operative dentistry. 610-20.
10. Devoto W, Saracinelli M, Manauta J. Composite in everyday practice: how to choose the right material and simplify application techniques in the anterior teeth. Eur J Esthet Dent. 2010; 5: 102-24.
11. Abu-Hussein M, Watted N, Abdulgani A, et al. Anterior Dental Esthetics in Primary Teeth. International Journal of Public Health Research. 2015; 3: 25-36.
12. Abu-Hussein M, Sarafianou A, Abdulgani Az, et al. The Color of Primary Teeth: A Literature Review. International Journal of Prosthetic Dentistry. 2013; 4: 70-74.

-
13. Abdulgani Azzaldeen, Alsagheeh Maria, Abu-Hussein Muhamad. Aesthetic Management of Fractured Anteriors: A Case Report. *American Research Journal of Dentistry*. 2021; 3: 1-6.
 14. Abu-Hussein Muhamad, Abdulgani Azzaldeen, Abdulgani Mai. Step-by-Step Approaches for Anterior Direct Restorative. *Int J Dent Health Sci*. 2015; 2: 1305-1310.
 15. Abu-Hussein M. Tooth fragment reattachment: An esthetic biological restoration. *World J Dent*. 2012; 3: 91-94.
 16. Abu-Hussein M. Tooth fragment reattachment: fundamentals of the technique and two case reports. *Quintessence Int*. 2003; 34: 99-107.
 17. Nahsan FP, Mondelli RF, Franco EB, et al. Clinical strategies for esthetic excellence in anterior tooth restorations: Understanding color and composite resin selection. *J Appl Oral Sci*. 2012; 20: 151-156.
 18. Sakai VT, Anzai A, Silva SMB, et al. Predictable esthetic treatment of fractured anterior teeth: A clinical report. *Dent Traumatol*. 2007; 23: 371-375.
 19. Borssen E, Holm AK. Treatment of traumatic dental injuries in a cohort of 16-year-olds in northern Sweden. *Endod Dent Traumatol*. 2000; 16: 276-281.
 20. Hamilton FA, Hill FJ, Holloway PJ. An investigation of dentoalveolar trauma and its treatment in an adolescent population. Part 1: the prevalence and incidence of injuries and the extent and adequacy of treatment received. *Br Dent J*. 1997; 182: 91-5.
 21. Kaste LM, Gift HC, Bhat M, et al. Prevalence of incisor trauma in persons 6–50 years of age: United States, 1988–1991. *J Dent Res*. 1996; 75: 696-705.
 22. Petti S, Tarsitani G. Traumatic injuries to anterior teeth in Italian schoolchildren: prevalence and risk factors. *Endod Dent Traumatol*. 1996; 12: 294-7.
 23. Vijayaraghavan TV, Hsiao J. Flexural behaviour of visible light cured composites as a function of temperature under water immersion test conditions. *Dent Mater*. 1994; 10: 347-52.
 24. Martin N, Jedynakiewicz N. Measurement of water sorption in dental composites. *Biomaterials*. 1998; 19: 77-83.
 25. Melo LL. *Traumatismo alvéolo-dentário*. 1. ed. Série EAP-APCD, v. 9. São Paulo: Artes Médicas; 1998.
 26. Melo REVA, Silva MBL, Vitor CMA, Luna LA, Firmo ACB. Traumatismo dentoalveolar. *Int J Dent*. 2003; 2: 266-272.